

Reconstructive Application of the Endotine Suspension Devices

James H. Boehmler IV, MD; Benjamin L. Judson, MD; Steven P. Davison, MD, DDS

Objective: To illustrate the potential reconstructive opportunities that the Endotine suspension devices can provide for patients with soft tissue ptosis secondary to facial nerve dysfunction, posttraumatic deformity, and postablative deformity.

Methods: A review was performed of 23 Endotine midface and eyebrow suspension devices in 10 patients with facial nerve sacrifice, facial trauma, or tumor extirpation.

Results: A total of 12 midface and 11 eyebrow suspension devices were used in 10 patients. All patients had improvement in soft tissue support and contour. The mean follow-up time was 10 months (range, 1-24 months). No major complications were noted. One patient had recur-

rent cellulitis secondary to maxillary sinusitis, and another had recurrent cellulitis that responded to treatment with intravenous antibiotics. The Endotine midface device was resistant to infection and did not require removal in either case. One patient requested revision surgery for resuspension of the eyebrow.

Conclusions: The Endotine midface and eyebrow suspension devices have been shown to be excellent methods of fixation in cosmetic eyebrow-lifts and midface-lifts. We have demonstrated that the Endotine device may be a good reconstructive option for patients with soft tissue ptosis in a multitude of scenarios.

Arch Facial Plast Surg. 2007;9(5):328-332

SOFT TISSUE SUPPORT IS AN ever-increasing concern for patients undergoing a variety of reconstructive surgical procedures. Following facial trauma and repair with open reduction and internal fixation techniques, the soft tissues of the midface can fall as a result of gravity, causing asymmetries.¹⁻⁴ Likewise, patients with cranial nerve VII dysfunction (eg, Bell palsy, neoplasm, trauma) can lose soft tissue support as well as facial animation.^{5,6} Last, patients who have undergone extirpative procedures for cancer can lose soft tissue support with their reconstructions.⁷

The Endotine midface⁸ and eyebrow⁹ suspension devices (Coapt Systems, Palo Alto, California) have been used extensively in cosmetic surgery for the last several years (**Figure 1** and **Figure 2**). They are bioabsorbable polylactic acid constructs placed in a subperiosteal plane for the support of soft tissue. For both midface and eyebrow suspension, ease of use and adjustability of suspension have been touted as benefits compared with traditional methods of soft tissue suspension, including soft tissue excision (direct or

coronal eyebrow-lift) or suture methods (eyebrow and midface).

To date, the Endotine devices have only been used in cosmetic surgery. The goal of this article is to illustrate the potential reconstructive opportunities that the Endotine devices can provide for patients with soft tissue ptosis secondary to facial nerve dysfunction, posttraumatic deformity, and postablative deformity.

METHODS

Ten patients had a total of 23 Endotine suspension devices (12 midface and 11 eyebrow) implanted that were placed for several different reconstructive goals (**Table**). The Endotine eyebrow device is an anchoring system for eyebrow-lifting after subperiosteal elevation of the eyebrow and any necessary release of periosteum, scar, or muscle. Either endoscopic or traditional open methods of surgical release can be performed. The tines are positioned according to where maximum pull of the eyebrow is desired by the surgeon. A specific hand drill or low-speed electrical drill is used to make a unicortical hole for the tines. The Endotine eyebrow device is then snapped into the drilled hole and oriented downward (**Figure 3**). The scalp is then

Author Affiliations:
Department of Plastic and Reconstructive Surgery (Drs Boehmler and Davison) and Department of Otolaryngology (Dr Judson), Georgetown University Hospital, Washington, DC.




Figure 1. The Endotine eyebrow suspension device (Coapt Systems, Palo Alto, California). The plug on the right is snapped into a hole made in bone with a hand drill. The tines on the left anchor the soft tissue for suspension. (Reprinted with permission from Coapt Systems.)




Figure 2. The Endotine midface suspension device (Coapt Systems, Palo Alto, California). The tines grab midface tissues subperiosteally, and the extension bar is tunneled to the deep temporal fascia for suturing. (Reprinted with permission from Coapt Systems.)

Table. Patients and Procedures

| Patient No./ Age, y | Etiology | Type of Endotine Device Used ^a | Duration of Follow-up, mo | Complications | Other Procedures and Comments |
|------------------------|---|--|------------------------------|-------------------------|---|
| 1/55 | Right zygoma fracture, right LeFort I fracture | Right eyebrow, bilateral midface | 24, 5 | None | Left direct eyebrow-lift, right cervicofacial rotation flap; right upper blepharoplasty and canthoplasty |
| 2/49 | Polio-associated facial nerve paralysis (incomplete) | Right midface, bilateral eyebrow | 14, 10 | Eyebrow resuspension | Revision eyebrow-lift 4 mo later (patient wished for more suspension), lower eyelid surgery and right gold weight with oculoplastic surgeon |
| 3/30 | Facial nerve sacrifice from acoustic neuroma resection | Right midface, right eyebrow | 11, 11 | None | Sural nerve cable graft; patient was to undergo gracilis free muscle transfer at later date |
| 4/63 | Buccal SCC, with prior fibula flap (removed with recurrence), with recon bar and pectoralis flap; Buccal branch of CN VII sacrificed | Right midface | 15 | Cellulitis | Flap debulking and vermilion revision (at time of midface-lift); patient had several bouts of cellulitis that responded to antibiotics |
| 5/50 | Idiopathic Bell palsy | Left eyebrow | 11 | None | Prior static sling and temporalis flap; left blepharoplasty and canthopexy |
| 6/48 | Idiopathic Bell palsy | Bilateral midface, bilateral eyebrow | 5, 5 | None | Multiple prior slings on left side |
| 7/26 | Gunshot wound with blow-out ZMC complex | Right midface | 10 | Cellulitis | Recurrent cellulitis secondary to maxillary sinusitis (device not removed); resolved with endoscopic sinus surgery |
| 7/48 | Idiopathic Bell palsy | Bilateral eyebrow, bilateral midface | 20, 12 | None | Left cosmetic face-lift, bilateral blepharoplasties |
| 8/74 | Bell palsy (later diagnosed as adenocarcinoma of right parotid) | Bilateral eyebrow, right midface | 3, 3 | None | At 3 mo after surgery patient was diagnosed as having a malignant parotid tumor and treated with parotidectomy and neck dissection |
| 9/47 | Right ZMC fracture | Right midface | 1 | None | None |

Abbreviations: CN, cranial nerve; recon bar, reconstruction bar; SCC, squamous cell carcinoma; ZMC, zygomaticomaxillary complex.

^aCoapt Systems, Palo Alto, California.

raised over the device, and the soft tissues are pushed into the tines so that they grasp the periosteum (**Figure 4** and **Figure 5**). If, after examination, the position of the eyebrow is not adequate, the soft tissues can be released by gentle traction and reset into the tines.

The Endotine midface device can be approached through either a temporal or oral retrograde fashion (**Figures 6, 7, and 8**). Subperiosteal dissection of the midface is performed. The Endotine midface device is inserted through a temporal incision subperiosteally, and the tines are engaged to the deep tissues. Ad-

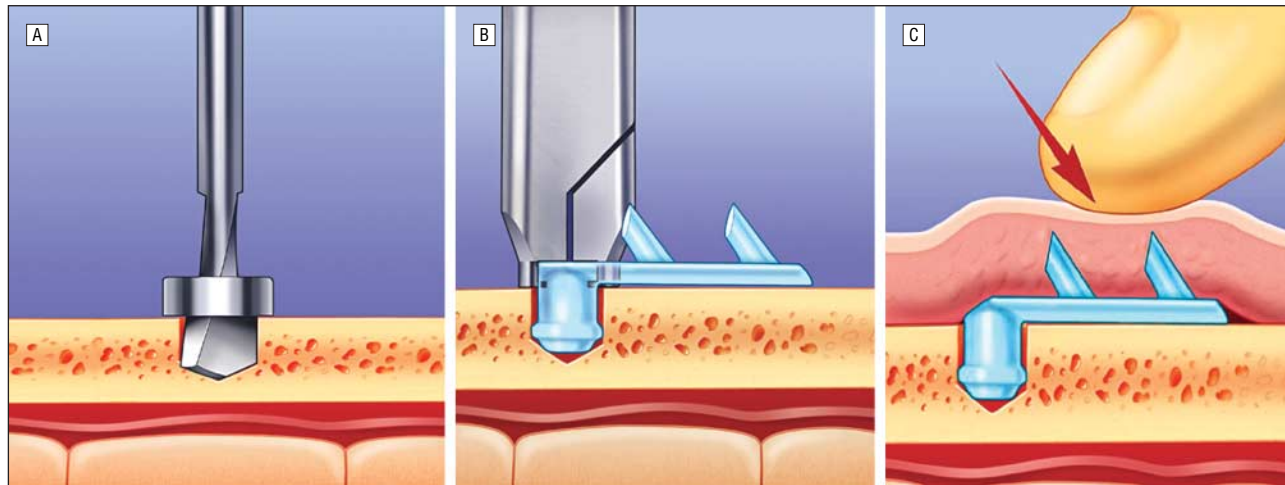


Figure 3. Application of the Endotine eyebrow suspension device (Coapt Systems, Palo Alto, California). A, A unicortical hole is drilled with the supplied hand drill. B, The device is snapped into place in the appropriate vector. C, Forehead tissue is pulled over the tines and set. (Reprinted with permission from Coapt Systems.)

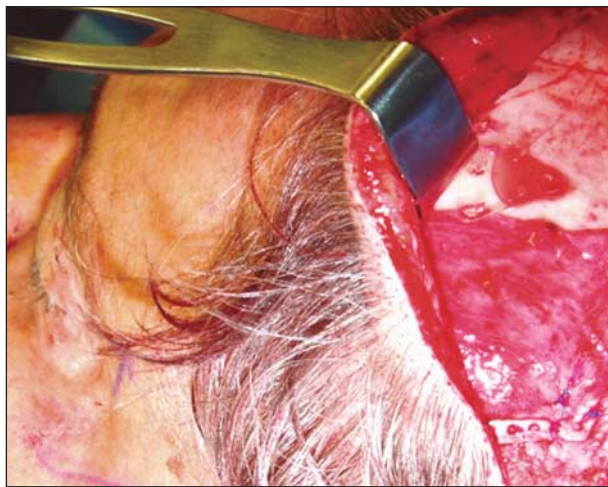


Figure 4. Intraoperative view showing an Endotine eyebrow suspension device (Coapt Systems, Palo Alto, California) placed during a coronal eyebrow-lift. Note the midface device anchored to the deep temporal fascia inferiorly.

equate pull is applied according to the surgeon's preference, and the Endotine device is attached to the deep temporal fascia with suture. Like the eyebrow device, the midface device can be disengaged and replaced as needed.

RESULTS

The mean duration of follow-up of patients was 10 months (range, 1-24 months) (**Figure 9**). One patient with a transfacial gunshot wound through the maxillary sinus developed recurrent cellulitis, which was caused by maxillary sinusitis. On surgical exploration, the Endotine midface device was not infected. The patient underwent endoscopic sinus surgery with resolution of the cellulitis. The device did not need to be removed. Another patient with recurrent cellulitis from the mandibular reconstruction was successfully treated with intravenous antibiotics, and the Endotine midface device did not need to be removed (**Figure 10**). One patient underwent revision of the eyebrow-lift 4 months after the original implan-

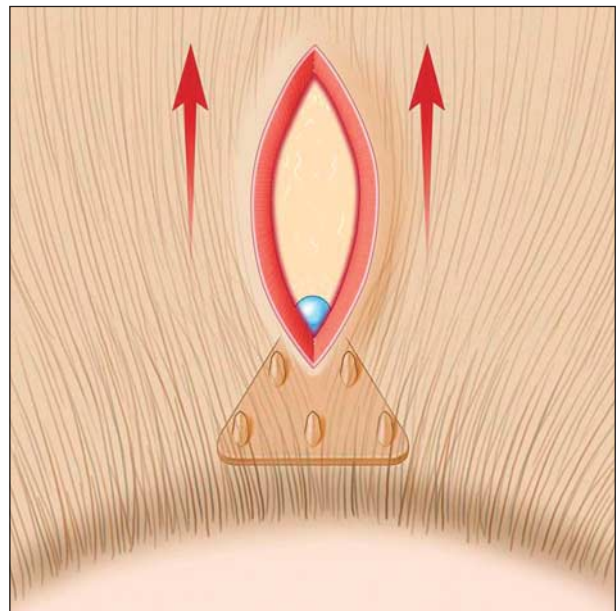


Figure 5. Schematic drawing showing the correct orientation and pull vector of the Endotine eyebrow suspension device (Coapt Systems, Palo Alto, California). (Reprinted with permission from Coapt Systems.)

tation of the Endotine eyebrow device secondary to inadequate suspension. The secondary surgery (with the new Endotine eyebrow device placement) was successful. All other patients had stable soft tissue support through the follow-up period. There were no cases of wound dehiscence, facial nerve injury, or hematoma.

COMMENT

Soft tissue ptosis in the face can be seen in various scenarios outside of the aging process. Loss of facial mimetic tone, either through facial nerve dysfunction (ie, Bell palsy) or facial nerve sacrifice (eg, owing to an acoustic neuroma or parotid tumor), prevents the skin and soft tissues from remaining in their correct anatomic locations. In the setting of facial nerve dysfunction, com-

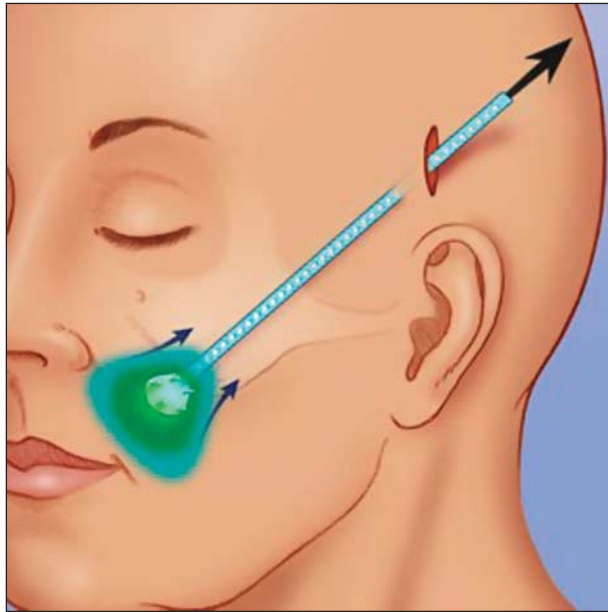


Figure 6. Schematic drawing showing the correct vector for the Endotine midface suspension device (Coapt Systems, Palo Alto, California). (Reprinted with permission from Coapt Systems.)

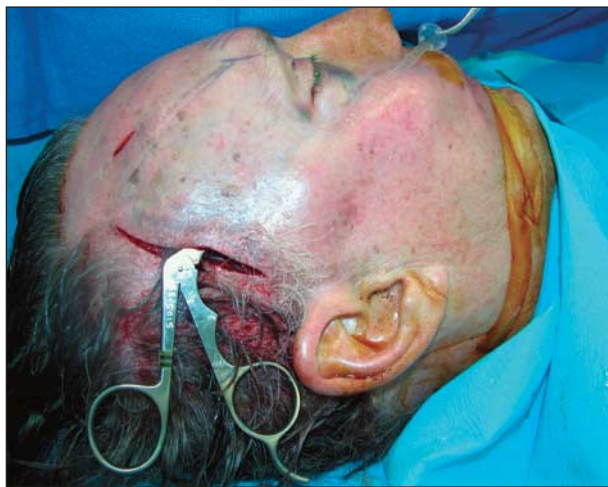

Figure 7. The Endotine midface suspension device (Coapt Systems, Palo Alto, California) placed through an oral retrograde approach.

monly addressed issues include adequate eye closure and oral commissure competence. Many treatments, including suture techniques, fascial grafts, and facial reanimation procedures, are geared toward these fundamental issues. However, less attention has been paid to the soft tissue contours of the eyebrow and midface.

Likewise, only within the past 15 years have surgeons become concerned about soft tissue redraping after reduction and fixation of fractures. The main advantage of soft tissue suspension, especially in the midface, is the decreased incidence of ectropion. Most repairs described involve suture techniques of resuspending the periosteum to the orbital rim or deep temporal fascia. Although these techniques have proven very useful to many surgeons, at times the sutures can pull out, especially if the periosteum has been damaged either from the trauma or during operative dissection. In addition, braided su-

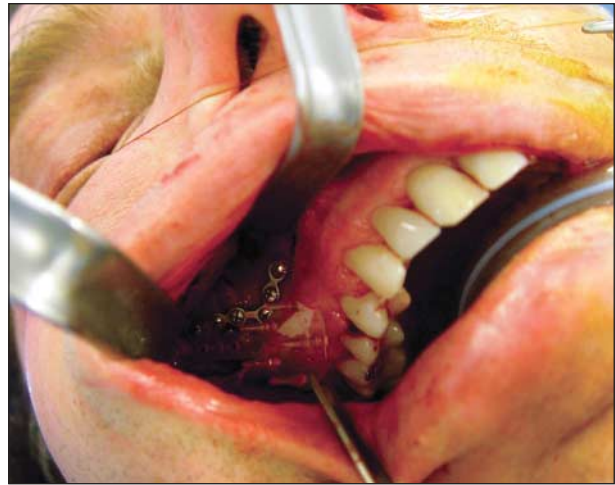

Figure 8. An oral view of the Endotine midface suspension device (Coapt Systems, Palo Alto, California) prior to fixation.

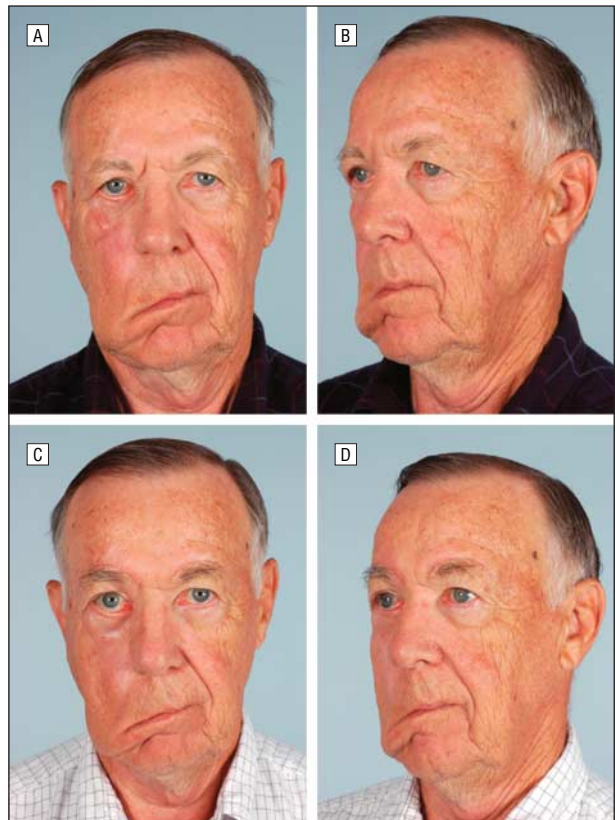


Figure 9. Patient 8, a 74-year-old man with a 2-year history of right-sided Bell palsy. The patient had had a prior gold weight and right lateral canthopexy. A, Anterior, and B, three-quarter preoperative views. C, Anterior, and D, three-quarter 3-month postoperative views after bilateral eyebrow-lift and right midface-lift with the Endotine suspension device (Coapt Systems, Palo Alto, California).

ture material can become infected and necessitate operative exploration and removal.

The Endotine devices have been around for several years in the cosmetic surgery community for soft tissue suspension with eyebrow-lifts and midface-lifts. The benefits of these devices in reconstructive surgery are numerous. The wide tines on both the eyebrow and mid-

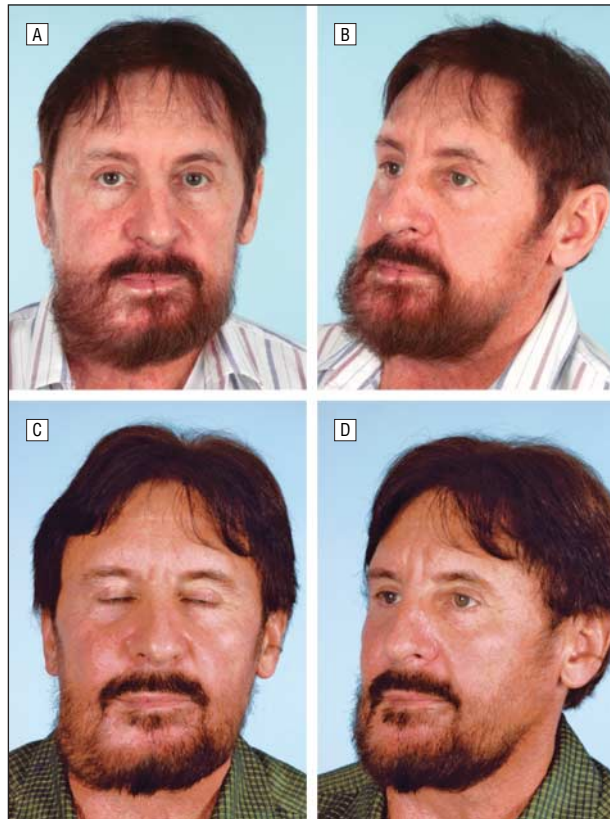


Figure 10. Patient 4, a 63-year-old man with a history of oral squamous cell carcinoma, segmental mandibulectomy with radiation therapy, and reconstruction bar and pectoralis major muscle reconstruction. A, Anterior, and B, three-quarter preoperative views. C, Anterior, and D, three-quarter 11-month postoperative views after flap debulking and right Endotine midface suspension device placement (Coapt Systems, Palo Alto, California). This patient had several bouts of cellulitis that eventually responded to intravenous antibiotics. Neither the Endotine device nor his reconstruction bar needed to be removed.

face devices allow for excellent tissue anchoring. If the periosteum had been traumatized previously, the tines can frequently get adequate purchase in the soft tissues. Also, the device can be easily placed and readjusted as necessary in the operating room to achieve the desired soft tissue suspension. Even though the device may be palpable postoperatively, it completely dissolves within 6 to 9 months, well after the healing process has been able to keep tissues suspended. In the 2 patients who had recurrent cellulitis, the Endotine midface device never became infected or needed to be removed. Even though they are not incorporated into tissue, the devices do seem to be resistant to infection. Further study will be neces-

sary to determine if the infection rate in Endotine devices is truly lower than that in suture methods.

In conclusion, the Endotine eyebrow and midface suspension devices can be useful adjuncts in the treatment of patients who require soft tissue resuspension after cancer extirpation, facial nerve dysfunction, or posttraumatic soft tissue deformity. These devices may be more resistant to infection than other implants or suture materials.

Accepted for Publication: February 6, 2007.

Correspondence: James H. Boehmler IV, MD, Department of Plastic Surgery, Georgetown University Hospital, PHC Bldg, 3800 Reservoir Rd, First Floor, Washington, DC 20007 (jayboehmler@mac.com).

Author Contributions: *Study concept and design:* Boehmler and Davison. *Acquisition of data:* Boehmler and Judson. *Analysis and interpretation of data:* Boehmler, Davison, and Judson. *Drafting of the manuscript:* Boehmler and Judson. *Critical revision of the manuscript for important intellectual content:* Boehmler and Davison. *Statistical analysis:* Boehmler and Judson. *Administrative, technical, and material support:* Boehmler, Davison, and Judson. *Study supervision:* Davison.

Financial Disclosure: None reported.

Previous Presentation: This article was presented at the Annual Meeting of the Northeastern Society of Plastic Surgeons; November 6, 2005; Washington, DC.

REFERENCES

1. Yaremchuk MJ, Kim WK. Soft-tissue alterations associated with acute, extended open reduction and internal fixation of orbital fractures. *J Craniofac Surg.* 1992; 3(3):134-140.
2. Ellis E. Advances in maxillofacial trauma surgery. In: Fonseca RJ, ed. *Oral and Maxillofacial Trauma.* St Louis, MO: Elsevier Saunders; 2005:329-375.
3. Phillips JH, Gruss JS, Wells MD, et al. Periosteal suspension of the lower eyelid and cheek following subciliary exposure of facial fractures. *Plast Reconstr Surg.* 1991;88(1):145-148.
4. Forrest CR, Antonyshyn OM. Acute management of complex facial fractures. *Oper Tech Plast Reconstr Surg.* 1998;5:188-200.
5. Freeman BS. Review of long-term results in supportive treatment of facial paralysis. *Plast Reconstr Surg.* 1979;63(2):214-218.
6. Sykes JM, TerKonda R. Esthetic procedures for rehabilitation of the paralyzed face. *Facial Plast Surg Clin North Am.* 1997;5:267-278.
7. Davison SP, Boehmler JH, Ganz JC, et al. Vascularized rib for facial reconstruction. *Plast Reconstr Surg.* 2004;114(1):15-20.
8. Saltz R. Endoscopic temporal-incision only midface lift is enhanced by Endotine technique. *Aesthetic Surg J.* 2005;25(1):80-83.
9. Stevens WG, Apfelberg DB, Stoker DA, et al. The Endotine: a new biodegradable fixation device for endoscopic forehead lifts. *Aesthetic Surg. J.* 2003;23(2): 103-107.